



blood

2012 120: 243-244
doi:10.1182/blood-2012-05-427419

Forecasting the future for patients with hereditary TTP

James N. George

Updated information and services can be found at:

<http://bloodjournal.hematologylibrary.org/content/120/2/243.full.html>

Articles on similar topics can be found in the following Blood collections

Information about reproducing this article in parts or in its entirety may be found online at:

http://bloodjournal.hematologylibrary.org/site/misc/rights.xhtml#repub_requests

Information about ordering reprints may be found online at:

<http://bloodjournal.hematologylibrary.org/site/misc/rights.xhtml#reprints>

Information about subscriptions and ASH membership may be found online at:

<http://bloodjournal.hematologylibrary.org/site/subscriptions/index.xhtml>

reduced access of eosin-maleimide to CD 47, band 3, and Rh protein. Why this should occur in HS is not clear.

We look forward to see use of this experimental design in studying splenic RBC removal in autoimmune hemolytic anemia.

Conflict-of-interest disclosure: The author declares no competing financial interests. ■

REFERENCES

1. Safeukui I, Buffet PA, Deplaine G, et al. Quantitative assessment of sensing and sequestration of spherocytic erythrocytes by the human spleen. *Blood*. 2012;120(2):424-430.

2. Low PS, Waugh SM, Zinke K, Drenckhahn D. The role of hemoglobin denaturation and band 3 clustering in red blood cell aging. *Science*. 1985;227(4686):531-533.

3. Mohandas N, Clark MR, Jacobs MS, Shohet SB. Analysis of factors regulating erythrocyte deformability. *J Clin Invest*. 1980;66(3):563-573.

4. Zarychanski R, Schulz VP, Houston BL, et al. Mutations in the mechanotransduction protein PIEZO1 are associated with hereditary xerocytosis [published online ahead of print April 23, 2012]. *Blood*. doi:10.1182/blood-2012-04-422253.

5. Bianchi P, Fermo E, Vercellati C, et al. Diagnostic power of laboratory tests for hereditary spherocytosis: a comparison study in 150 patients grouped according to molecular and clinical characteristics. *Haematologica*. 2012;97(4):516-523.

● ● ● THROMBOSIS & HEMOSTASIS

Comment on Lotta et al, page 440

Forecasting the future for patients with hereditary TTP

James N. George UNIVERSITY OF OKLAHOMA HEALTH SCIENCES CENTER

Hereditary thrombotic thrombocytopenic purpura (TTP) may be rare, but it is forever. What is the future for our patients?

Hereditary TTP, caused by *ADAMTS13* mutations resulting in a severe deficiency of ADAMTS13 activity, is also known as Upshaw-Schulman syndrome. In 1960, Schulman et al reported an 8-year-old girl who had repeated episodes of thrombocytopenia that responded to plasma infusion; they concluded that she had a “congenital deficiency of a platelet-stimulating factor.”¹ In 1978, Upshaw et al reported a 29-year-old woman who had repeated episodes of TTP.² These 2 patients were among the 4 patients with chronic relapsing TTP studied by Moake et al in 1982, demonstrating the presence of unusually large von Willebrand factor (VWF) multimers and postulating a missing factor required for VWF cleavage.³ The missing factor was initially identified as a VWF-cleaving protease in 1997 in a patient with hereditary TTP⁴ and subsequently characterized in 2001 as ADAMTS13 in a study of 4 families with hereditary TTP.⁵ This is a wonderful scientific story, but then the next question is, what happens to people with a lifetime deficiency of ADAMTS13?

The experience of Fujimura et al with 43 patients from Japan documents the heterogeneity of hereditary TTP.⁶ Eighteen (42%) had severe neonatal hemolysis requiring exchange transfusion; 25 (58%) were diagnosed as children; 15 (35%) were 15 to 45 years old

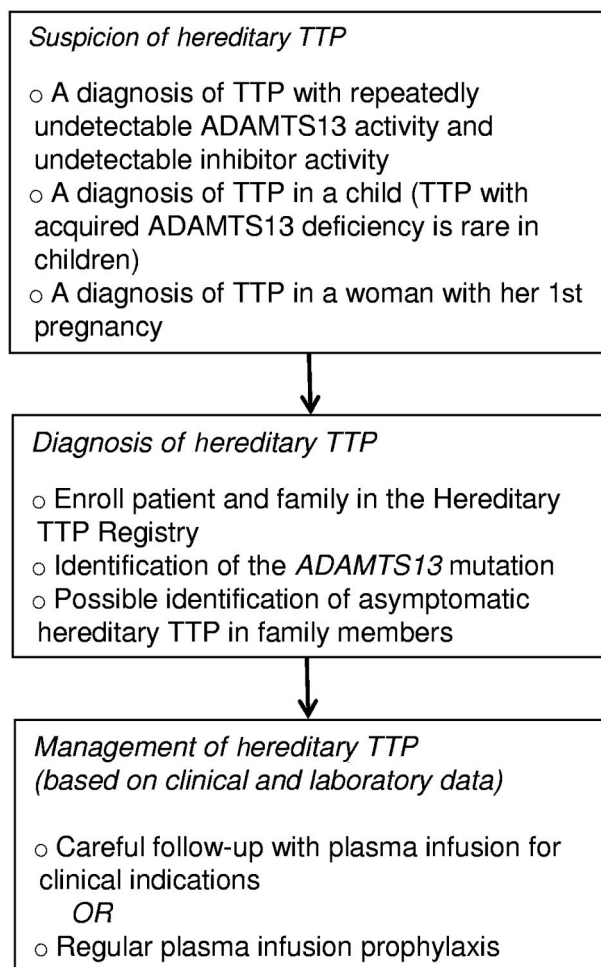
when they were diagnosed, 7 in association with pregnancy; 3 (7%) were 51 to 63 years old when TTP suddenly developed. Fujimura et al postulated that some ADAMTS13 mutations may result in a mild, late-onset phenotype, without manifestations of overt TTP unless additional factors, such as pregnancy or infection, are present.⁶

These observations are extended by Lotta et al in this issue of *Blood*.⁷ They describe 29 patients with hereditary TTP in 25 families from 4 centers across Europe. Using an assay with sensitivity to 0.5%, 26 patients had measurable ADAMTS13 activity (range, 0.5%-6.8%); 31 different *ADAMTS13* mutations were identified. The severity of the deficiency of ADAMTS13 activity correlated with younger age of the first TTP episode, a higher frequency of TTP episodes, and the use of regular plasma prophylaxis. *ADAMTS13* mutations affecting the highly conserved N-terminal domains of ADAMTS13 were associated with lower residual ADAMTS13 activity and more severe clinical features. These data provide a basis for understanding the genetic heterogeneity of hereditary TTP, similar to the heterogeneity of hemophilia related to residual factor VIII or IX activity. However, Lotta et al also observed exceptions; some patients with higher ADAMTS13 activ-

ity had early onset and frequent recurrences of acute episodes. These observations emphasize that multiple additional factors are important for triggering acute episodes of microvascular thrombosis, similar to other thrombotic disorders. Pregnancy appears to be a particular hazard for women with hereditary TTP.^{6,8}

Until 3 months ago I thought that hereditary TTP was too rare for clinicians to care about. I had not recognized a patient with hereditary TTP since 1974.⁹ Then we diagnosed hereditary TTP in a teenage girl and subsequently in both of her younger teenage sisters. All 3 girls had required exchange transfusion at birth for severe hemolysis and thrombocytopenia; the oldest sister had a focal seizure and small cerebral thrombosis on her first day of life that promptly resolved. At that time, these episodes were attributed (with some uncertainty) to their other clinically apparent hereditary disorder, elliptocytosis. Subsequently all 3 girls have had excellent health except for 3 episodes of transient, asymptomatic thrombocytopenia: 2 in the youngest sister, 1 in the oldest. They are all outstanding students and athletes. My conversations with this family around their kitchen table have been all about forecasting the future. We’ve discussed potential problems and developed management plans for the near future, but what about the next 75 years? Other than for pregnancies, should plasma infusions be given only when there is evidence of TTP? What are the relative benefits and risks of regular prophylactic plasma infusions?¹⁰ What about the girls’ risks for kidney disease, hypertension, and cardiovascular disease; should these be anticipated and can they be prevented? The patient reported by Schulman et al¹ developed renal failure and became dialysis dependent.¹⁰ Experimental data suggest that ADAMTS13 deficiency can accelerate the development of atherosclerosis.¹¹ These observations emphasize the potential dangers in the decades ahead for my patients.

To answer these questions about the future of patients with hereditary TTP, systematic lifetime follow-up of many patients will be required. To achieve this, an international Hereditary TTP Registry (www.ttpregistry.net; NCT 01257269) was established in 2009; 83 patients from 74 families in 18 countries have been enrolled. Genetic data and detailed clinical observations from long-term follow-up will determine the risk for renal, cardiac, or cognitive problems in patients with



Detection and management of patients with hereditary TTP. The Hereditary TTP Registry (www.ttpregistry.net; NCT 01257269, clinicaltrials.gov) is an observational study that provides genotyping and systematic long-term follow-up.

hereditary TTP and will help to determine appropriate management.

My recent experience has changed my opinion. Now I am convinced that hereditary TTP is an important, though rare, problem for clinicians. The first problem for clinicians is recognition (see figure). There are several situations that should stimulate suspicion for the diagnosis of hereditary TTP: the occurrence of thrombocytopenia and hemolytic anemia in a newborn infant; recurrent episodes of acute thrombocytopenia in a child; the diagnosis of TTP in a child, because acquired TTP is rare in children; TTP occurring during an initial pregnancy.^{6,8} Once suspected, the definitive genetic diagnosis of hereditary TTP is available. The next step is to determine appropriate management.¹⁰ Regular plasma infusions have logistical problems and potential risks that may be minimized by future availability of recombinant ADAMTS13. Management may be guided by our increasing knowledge of the

genetic heterogeneity of hereditary TTP.^{6,7} These data will allow us to translate research into practice and forecast the future with increasing confidence.

Conflict-of-interest disclosure: The author serves as a consultant for Baxter Healthcare for

the development of rADAMTS13 as a potential treatment for TTP and is a co-investigator for the Hereditary TTP Registry (www.ttpregistry.net; NCT 01257269), which is partially supported by a grant from Baxter Healthcare. ■

REFERENCES

- Schulman I, Pierce M, Lukens A, Currimbhoy Z. Studies on thrombopoiesis: I. A factor in normal plasma required for platelet production: chronic thrombocytopenia due to its deficiency. *Blood*. 1960;16(1):943-957.
- Upshaw JD Jr. Congenital deficiency of a factor in normal plasma that reverses microangiopathic hemolysis and thrombocytopenia. *N Engl J Med*. 1978;298(24):1350-1352.
- Moake JL, Rudy CK, Troll JH, et al. Unusually large plasma factor VIII: von Willebrand factor multimers in chronic relapsing thrombotic thrombocytopenic purpura. *N Engl J Med*. 1982;307(23):1432-1435.
- Furlan M, Robles R, Solenthaler M, Wassmer M, Sandoz P, Lämmle B. Deficient activity of von Willebrand factor-cleaving protease in chronic relapsing thrombotic thrombocytopenic purpura. *Blood*. 1997;89(9):3097-3103.
- Levy GG, Nichols WC, Lian EC, et al. Mutations in a member of the ADAMTS gene family cause thrombotic thrombocytopenic purpura. *Nature*. 2001;413(6855):488-494.
- Fujimura Y, Matsumoto M, Isonishi A, et al. Natural history of Upshaw-Schulman syndrome based on ADAMTS13 gene analysis in Japan. *J Thromb Haemost*. 2011;9(Suppl 1):283-301.
- Lotta LA, Wu HM, Mackie IJ, et al. Residual plasmin activity of ADAMTS13 is correlated with phenotype severity in congenital thrombotic thrombocytopenic purpura. *Blood*. 2012;120(2):440-448.
- Moatti-Cohen M, Garrec C, Wolf M, et al. Unexpected frequency of Upshaw-Schulman syndrome in pregnancy-associated thrombotic thrombocytopenic purpura [published online ahead of print April 30, 2012]. *Blood*. doi: 10.1182/blood-2012-02-408914.
- Fuchs WE, George JN, Dotin LN, Sears DA. Thrombotic thrombocytopenic purpura. Occurrence two years apart during late pregnancy in two sisters. *JAMA*. 1976;235(19):2126.
- George JN. Congenital thrombotic thrombocytopenic purpura: Lessons for recognition and management of rare syndromes. *Pediatr Blood Cancer*. 2008;50(5):947-948.
- Gandhi C, Khan MM, Lentz SR, Chauhan AK. ADAMTS13 reduces vascular inflammation and the development of early atherosclerosis in mice. *Blood*. 2012;119(10):2385-2391.

● ● ● TRANSPLANTATION

Comment on Leung et al, page 468

Pretransplant MRD: the light is yellow, not red

Alan S. Wayne and Jerald P. Radich NATIONAL CANCER INSTITUTE; FRED HUTCHINSON CANCER RESEARCH CENTER

In the study reported in this issue of *Blood* by Leung et al, detectable minimal residual disease (MRD) before hematopoietic stem cell transplantation (HSCT) was found to be prognostic for outcome, but did not prevent cure for children with acute lymphoblastic leukemia (ALL) and acute myeloid leukemia (AML).¹